



NATIONAL COMPETENCY PROFILES

**GENERALIST SONOGRAPHER
CARDIAC SONOGRAPHER
VASCULAR SONOGRAPHER**

**Version 6.1
JULY 2019**

**Version 6.0 Approved by the Board of Directors, July 17, 2019
Re-issued as Version 6.1, October 6, 2021**

Adopted for use in the EQual™ Canada Accreditation Process, November 28, 2019

® a registered trademark of Sonography Canada / Échographie Canada

Table of Contents

Preamble.....	3
Purpose of the National Competency Profiles	4
Conceptual Framework and Definitions	4
Structure of the National Competency Profiles.....	5
Use of the National Competency Profiles.....	6
1.0 Communication.....	7
2.0 Professional Responsibilities.....	8
3.0 Patient Assessment and Care	10
4.0 Imaging.....	11
5.0 Critical Thinking and Problem Solving	13
6.0 Workplace Health and Safety	15
Glossary of Terms	16
Appendices.....	19
Appendix A: Examination Techniques for the Generalist Sonographer – OBSTETRICS & GYNECOLOGY	20
Appendix B: Examination Techniques for the Generalist Sonographer – ABDOMEN.....	24
Appendix C: Examination Techniques for the Generalist Sonographer – SUPERFICIAL STRUCTURES.....	26
Appendix D: Examination Techniques for the Generalist Sonographer – PERIPHERAL VEINS.....	27
Appendix E: Examination Techniques for the Cardiac Sonographer	28
Appendix F: Examination Techniques for the Vascular Sonographer	30
Development and Validation of the National Competency Profiles	32
Acknowledgements.....	33

Preamble

Diagnostic medical sonographers are health care professionals who perform ultrasound examinations of the human body. As members of an integrated health care team, sonographers acquire images in a variety of formats and provide a technical impression of findings to an interpreting physician. The Canadian standard of practice for sonographers was established by Sonography Canada.

Sonography Canada is the certification body for three entry-level sonographer credentials:

Canadian Registered Generalist Sonographer (CRGS[®]) – denotes a sonographer who performs imaging of the abdomen, male and female pelvis, obstetrics, peripheral veins for DVT and superficial structures including (but not limited to) thyroid and scrotum.

Canadian Registered Cardiac Sonographer (CRCS[®]) – denotes a sonographer who performs imaging of adult cardiac anatomy, function, physiology, pathology and adult congenital assessment.

Canadian Registered Vascular Sonographer (CRVS[®]) – denotes a sonographer who performs vascular ultrasound imaging; which includes (but is not limited to) the abdominal vessels, peripheral arteries/veins, extra/intra cranial arteries/veins, and physiologic vascular assessments.

To grant these credentials, Sonography Canada assesses the knowledge, skills and judgement of applicants using both clinical and knowledge-based assessment examinations, the criteria for which are derived from the National Competency Profiles (NCPs).

Purpose of the National Competency Profiles

The National Competency Profiles (NCPs) list competencies that are expected at entry-to-practice for the three credentials. The primary purpose is to set standards for education and certification.

The profiles are used by the national accrediting organization for use in the accreditation of diagnostic medical sonography education programs. Accredited programs must develop curriculum and learning activities which ensure that graduates meet all the competencies listed in the relevant sections. The profiles establish *minimum* entry-to-practice educational standards therefore programs are free to include additional competencies to meet local and regional needs, at their discretion. The NCPs are also referred to by other stakeholders such as employers, physicians, provincial regulators, and government agencies.

Conceptual Framework and Definitions

Competence refers to the ability of a professional to practice safely, effectively and ethically. The competence of health care professionals is crucial to public safety and patient well-being.

Competence is:

- developmental - evolves over the span of a person's career;
- impermanent - knowledge and skills that are not regularly utilized are lost and
- context-specific - competence is not measurable in the absence of a specific practice situation.

Entry-level competence recognizes that an entry-to-practice sonographer is a novice in the profession. These sonographers will have varying levels of knowledge and skills: academic, simulated, and/or clinical (as defined on page 6).

When presented with routine situations, sonographers at this level should perform relevant competencies in a manner consistent with generally accepted standards in the profession independently and within a reasonable timeframe. Entry-level sonographers should anticipate which outcomes to expect in a given situation and respond appropriately, performing competencies in an informed manner.

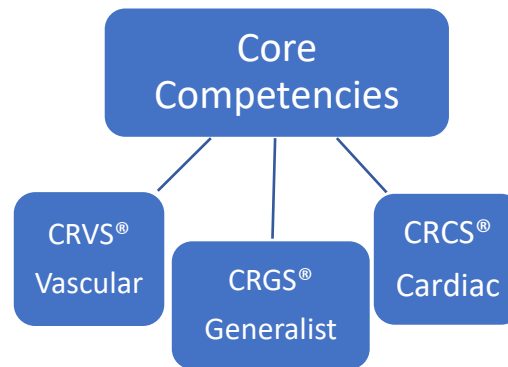
Structure of the National Competency Profiles

The competencies are grouped into the following areas:

1. Communication
2. Professional Responsibilities
3. Patient Assessment and Care
4. Imaging
5. Critical Thinking and Problem Solving
6. Workplace Health and Safety

Specific imaging techniques applicable to competency 4.2b are listed in Appendices A through F. A glossary of terms is also included.

Within each area and appendix, competencies are listed in a table, assigned an appropriate assessment environment, and organized for convenience. These competencies are not intended as scanning protocols. The CORE column outlines the fundamental competencies which are applicable to all three credentials (specialties). Within these specialty areas, each have a distinct set of associated skills/competencies.



Use of the National Competency Profiles

The National Competency Profiles (NCPs) designate the *Assessment Environment* for each competency which denotes the educational setting for assessing student proficiency. The appropriate environment is determined by national survey responses. Educators and student assessors are expected to have a comprehensive understanding of the NCPs. Employers should be familiar with the NCPs to manage entry-level expectations.

The following assessment environments are used:

Assessment Environment	Definition	Criterion for Student Success
A (Academic)	Academic education takes place in a classroom or through guided study involving cognitive and / or affective learning.	Academic assessment consistent with the definition of entry-level competence.
S (Simulation)	Simulation involves cognitive, affective and / or psychomotor learning in a setting that simulates a practice activity.	Simulated performance consistent with the definition of entry-level competence.
C (Clinical)	Clinical education involves cognitive, affective and / or psychomotor learning where learners work directly with human patients in a setting designed to provide patient care. Learners are supervised throughout their clinical education, in a manner that facilitates their development of independent clinical abilities while ensuring safe, effective and ethical patient care.	Reliable clinical performance consistent with the definition of entry-level competence.

1.0 Communication

Sonographers use effective and adaptive communication to ensure quality professional relationships are developed with patients, families, members of the health care team and other stakeholders.

1.0	COMMUNICATION	Core	Generalist	Cardiac	Vascular
1.1	Oral communication				
1.1a	Identify self to patient.	C			
1.1b	Adapt communication in response to patient and situation.	C			
1.1c	Adapt communication for patients with special needs.	S			
1.1d	Communicate with patient throughout examination, in manner appropriate to patient's ability to understand.	C			
1.1e	Explain examination procedure to patient.	C			
1.1f	Question patient to obtain relevant information regarding history and condition.	C			
1.1g	Communicate departmental reporting procedures to patient.	C			
1.1h	Respond to patient questions or concerns.	C			
1.1i	Communicate with patient's relatives and / or support persons.	C			
1.1j	Communicate with other health care professionals.	C			
1.1k	Use medical terminology and standard abbreviations in oral communication.	C			
1.1l	Apply conflict resolution strategies.	S			
1.2	Written communication				
1.2a	Verify written, authorized directions for examination.	C			
1.2b	Record accurate and relevant medical history.	C			
1.2c	Record examination procedures and results.	C			
1.2d	Ensure that documentation is timely, accurate, concise and complete.	C			
1.2e	Write medical terminology and standard abbreviations.	C			
1.3	Non-verbal communication				
1.3a	Use appropriate body language.	C			
1.3b	Respond appropriately to non-verbal behaviours.	C			

2.0 Professional Responsibilities

Sonographers, individually and as collaborative members of the health care team, facilitate the efficient use of resources and the implementation of technological developments to advance patient outcomes. As professionals, sonographers are committed to lifelong learning for continuous excellence in practice and adhere to regulatory guidelines and relevant code of ethics and conduct. This will guarantee every patient receives the best possible care and ensure the patient is always treated with respect and dignity.

2.0	PROFESSIONAL RESPONSIBILITIES	Core	Generalist	Cardiac	Vascular
2.1	Legal and ethical requirements				
2.1a	Adhere to relevant provincial and federal legislation and regulations.	A			
2.1b	Adhere to relevant professional scope of practice and code of ethics.	A			
2.1c	Adhere to institutional policies and procedures.	C			
2.1d	Comply with requirements of provincial regulatory body, including applicable Standards of Practice and sexual abuse prevention guidelines.	A			
2.1e	Maintain patient privacy and confidentiality.	C			
2.1f	Ensure informed patient consent.	C			
2.2	Professional judgement				
2.2a	Verify patient's identification.	C			
2.2b	Verify requested procedure correlates with patient's clinical history and presentation, and address concerns as appropriate.	C			
2.2c	Evaluate patient preparation for requested examination.	C			
2.2d	Practice within limits of personal knowledge, skill and judgement.	C			
2.2e	Ask for guidance where appropriate.	C			
2.2f	Evaluate for contraindications to procedure and address as appropriate.	C			
2.2g	Identify and respond to exceptions from established protocols and procedures.	C			
2.2h	Identify and respond to urgent sonographic findings.	C			
2.2i	Accept responsibility for decisions and actions.	C			

Continued on next page

2.0	PROFESSIONAL RESPONSIBILITIES	Core	Generalist	Cardiac	Vascular
2.3	Professional conduct				
2.3a	Maintain professional appearance and manner.	C			
2.3b	Provide care for patient in a manner that is respectful of individual diversity.	C			
2.3c	Understand the inter / intraprofessional roles commonly encountered in the workplace.	A			
2.3d	Collaborate with inter / intraprofessional team members in decision making.	S			
2.3e	Share knowledge with patients, colleagues, students and other members of health care team.	C			
2.3f	Provide and receive feedback in a professional manner.	C			
2.3g	Manage time and workload efficiently.	C			
2.3h	Demonstrate reliability.	C			
2.3i	Demonstrate adaptability.	C			
2.3j	Participate in patient education.	C			
2.3k	Recognize need for presence of a chaperone.	A			
2.3l	Recognize, respond to and disclose adverse events.	A			
2.3m	Demonstrate awareness of professional liability.	A			
2.3n	Maintain awareness of current and emerging issues in health care relevant to the practice of sonography.	A			
2.3o	Maintain awareness of current and emerging technological developments in the field of sonography.	A			
2.4	Maintenance of competence				
2.4a	Critically appraise performance and set goals for self-improvement.	C			
2.4b	Review professional literature and assess relevance to practice.	A			
2.4c	Demonstrate awareness of need for continuing professional development.	A			

3.0 Patient Assessment and Care

Sonographers integrate knowledge, skills and compassion to maintain dignity, comfort and safety of patients during clinical procedures and examinations.

3.0	PATIENT ASSESSMENT AND CARE	Core	Generalist	Cardiac	Vascular
3.1	Patient safety and comfort				
3.1a	Ensure safe and comfortable patient transporting, transferring and / or positioning.	S			
3.1b	Assess patient's ability to tolerate examination.	C			
3.1c	Employ sterile technique.	S			
3.1d	Employ universal precautions for infection control.	C			
3.1e	Assess and monitor patient's physical and mental status prior to and during examination and respond.	C			
3.1f	Create an environment that protects patient dignity.	C			
3.1g	Determine need for additional personnel to assist in examination.	C			
3.1h	Perform examination in a timely manner.	C			
3.1i	Maintain awareness of patient's accessory equipment and take action as required.	A			
3.1j	Recognize and respond to emergency situations.	S			
3.1k	Demonstrate knowledge of Basic Life Support training or equivalent.	S			
3.2	Clinical procedures				
3.2a	Understand role in interventional procedures.	A			
3.2b	Understand role in transesophageal echocardiography.			A	
3.3	Related techniques and procedures				
3.3a	Measure blood pressure.		A	S	C
3.3b	Perform palpation of pulses for examination.				C
3.3c	Perform palpation of areas of interest.		C		C
3.3d	Perform dynamic/ provocative maneuvers (e.g., Valsalva).	C			
3.3e	Understand the application of stress echocardiography.			A	
3.3f	Set up 3-lead electrocardiogram (ECG).			C	
3.3g	Assess for signs and symptoms of vascular disease.				C
3.3h	Understand the application of transrectal imaging.		A		
3.3i	Understand when to perform a transperineal / translabial scan.		A		
3.3j	Perform contrast-enhanced imaging.		A	A	A
3.3k	Perform intravenous starts.			S	S

4.0 Imaging

Sonographers are experts in using ultrasound as a diagnostic imaging tool by obtaining the required education and skills to ensure competence. They work to promote adherence to the recognized standards in their workplace, while acknowledging professional limitations, to provide the best possible examination for the patient.

4.0	IMAGING	Core	Generalist	Cardiac	Vascular
4.1	Equipment set-up				
4.1a	Select optimum system and transducer for examination considering patient's age and size, structures being examined and specific indications for examination.	C			
4.1b	Determine and select correct pre-set values.	C			
4.1c	Input patient data.	C			
4.2	Operation of Equipment				
4.2a	Orient and manipulate transducer.	C			
4.2b	Perform sonographic examination of structures of interest using knowledge of sonographic principles, instrumentation and techniques listed in Appendices A to F.				
	Obstetrics and Gynecology		Appendix A (pg 20)		
	Abdomen		Appendix B (pg 24)		
	Superficial Structures		Appendix C (pg 26)		
	Peripheral Veins		Appendix D (pg 27)		
	Cardiac			Appendix E (pg 28)	
	Vascular				Appendix F (pg 30)
4.2c	Monitor output display indices and adjust power output in accordance with "as low as reasonably achievable" (ALARA) principle.	C			
4.2d	Adjust instrument controls to optimize image.	C			
4.2e	Identify artifacts.	C			
4.2f	Record patient position and plane of section on images, as required.	C			
4.2g	Use software calculation packages.	C			
4.2h	Perform sonographic examinations using 3-D imaging.		A	A	

Continued on next page

4.0	IMAGING	Core	Generalist	Cardiac	Vascular
4.3	Equipment maintenance				
4.3a	Understand imaging and instrumentation activities included in quality assurance testing.	A			
4.3b	Identify degraded instrument performance.	A			
4.3c	Understand basic trouble shooting.	A			

5.0 Critical Thinking and Problem Solving

Sonographers must have the knowledge, skills and judgment necessary to perform a thorough examination, acquire and analyze data, and provide a professional account of sonographic findings.

5.0	CRITICAL THINKING AND PROBLEM SOLVING	Core	Generalist	Cardiac	Vascular
5.1	Examination planning				
5.1a	Interpret history, signs & symptoms and other relevant information.	C			
5.1b	Assess medical history and health status.	C			
5.1c	Modify scope of examination based on clinical history.	C			
5.1d	Formulate sonographic scanning strategies.	C			
5.1e	Integrate knowledge of anatomy and disease processes.	C			
5.2	Correlation of relevant diagnostic data				
5.2a	Correlate results from laboratory tests, aspirations and biopsies.	A			
5.2b	Correlate results from diagnostic imaging (radiography, computerized tomography, nuclear medicine and magnetic resonance studies).	A			
5.2c	Correlate results from obstetric testing (amniocentesis, chorionic villus sampling, chromosome analysis, cell free DNA, dilation and curettage, non-stress testing).		A		
5.2d	Correlate results from cardiac testing (ECG, Holter monitoring, stress ECG).			A	
5.2e	Correlate results from oximetry and / or auscultation.			A	A
5.3	Examination				
5.3a	Select optimal acoustic window.	C			
5.3b	Optimize patient position.	C			
5.3c	Employ breathing techniques.	C			
5.3d	Interrogate anatomy in required planes of section.	C			
5.3e	Evaluate images for orientation, identification, and labeling.	C			
5.3f	Evaluate images for quality.	C			
5.3g	Recognize sonographic appearance of normal structures.	C			
5.3h	Recognize artifacts and normal variants.	C			
5.3i	Differentiate artifact and normal variants from anatomic and pathologic findings.	C			
5.3j	Recognize and investigate abnormal findings.	C			
5.3k	Modify examination based on sonographic evidence, clinical information, resource implications and other contextual factors.	C			
5.3l	Ensure all applicable components of examination are complete.	C			
5.3m	Recognize equipment limitations.	C			
5.3n	Recognize technical limitations.	C			

Continued on next page

5.0	CRITICAL THINKING AND PROBLEM SOLVING	Core	Generalist	Cardiac	Vascular
5.4	Technical analysis				
5.4a	Produce diagnostic data documenting sonographic findings.	C			
5.4b	Formulate impression based on findings.	C			
5.4c	Understand the variables and their relationships within calculations.	A			
5.4d	Use spatial reasoning to interpret images.	C			
5.4e	Identify and prioritize differential findings.	C			
5.4f	Document limitations to exam quality and completeness.	C			
5.4g	Provide a technical impression to reporting physician.	C			

6.0 Workplace Health and Safety

It is essential that sonographers have and create a safe work environment while engaging in self-protection to maintain their own health and well-being.

6.0	WORKPLACE HEALTH AND SAFETY	Core	Generalist	Cardiac	Vascular
6.1	Safety of the work environment				
6.1a	Maintain clean and orderly work area.	C			
6.1b	Recognize hazardous conditions in the work area and respond.	C			
6.1c	Maintain awareness of fire and disaster plans.	A			
6.1d	Locate emergency equipment.	C			
6.2	Self protection				
6.2a	Employ proper body mechanics when transferring, positioning or transporting patient.	C			
6.2b	Practice ergonomic techniques.	C			
6.2c	Engage in practices to promote own physical and environmental safety.	C			
6.2d	Follow standardized procedures for handling and disposing of sharps, and contaminated and biohazardous materials.	A			

Glossary of Terms

Basic life support (BLS) training	BLS includes initial assessment, airway maintenance and CPR.
Body language	Body language is nonverbal communication where thoughts, intentions, or feelings are expressed by physical behaviors, such as facial expressions, body posture, gestures, eye movement, touch and the use of space.
Code of conduct	A set of rules outlining the social norms and rules and responsibilities of, or proper practices for, an individual, party, organization or profession.
Code of ethics	A code of professional responsibility, which will define difficult issues, difficult decisions that will often need to be made, and provide a clear account of what behavior is considered "ethical" or "correct" or "right" in the circumstances.
Collaborate	Work jointly on an activity.
Competence	The ability of a professional to practice safely, effectively and ethically.
Comply	Act in accordance with and/or meet specific standards.
Contrast-enhanced	The use of microbubble contrast agents and specialized imaging techniques to enhance visualization of structures, show sensitive blood flow and provide tissue perfusion information.
Correlate	To establish a mutual or reciprocal relation.
Differentiate	Recognize or ascertain what makes (someone or something) different.
Dynamic/provocative maneuvers	Techniques used to provoke a response. (ie: Valsalva)
Ergonomics	Ergonomics is the science of designing the workplace, keeping in mind the capabilities and limitations of the worker. A systematic ergonomics improvement process removes risk factors that lead to musculoskeletal injuries and allows for improved human performance and productivity.
Grading	The act of classifying something on a scale.
Infection control	Infection prevention and control (IPC) is a scientific approach and practical solution designed to prevent harm caused by infection to patients and health workers. It is grounded in infectious diseases, epidemiology, social science and health system strengthening.
Instrumentation	Basic components of the ultrasound equipment to perform key functions.
Interprofessional	Interprofessional care refers to care provided through collaboration between sonographers and other healthcare professionals.
Interrogate	To examine or investigate.

Continued on next page

Interventional procedures	Procedures used for diagnosis or treatment that involves incision; puncture; entry into a body cavity; or the use of ionizing, electromagnetic or acoustic energy.
Maintain	Cause or enable (a condition or state of affairs) to continue., to keep in an existing state.
Modify	Make partial or minor changes to (something), typically so as to improve it or to make it less extreme.
Non-verbal communication	Communication without the use of spoken language (see 'body language').
Optimize	To make something as good or effective as possible.
Patient	Could also be referred to as a client.
Patient privacy and confidentiality	National, provincial and institutional/employer laws and policies are in place which closely govern patient privacy and freedom to information for health records in all Canadian jurisdictions. It is the responsibility of the sonographer to be familiar with all laws and policies which apply to your workplace. A breach of these laws and policies may result in disciplinary action. Investigation of breaches of these laws and policies are not the responsibility of Sonography Canada and should be directed to the appropriate workplace or government authority. Provincial standards can be found on page 37 of the Sonography Canada Professional Practice Guidelines and Member Policies .
Patient safety	The prevention of errors and adverse effects to patients associated with health care.
Professional liability	Legal obligations arising out of a professional's errors, negligent acts, or omissions during the course of the practice of his or her craft.
Provincial and federal legislation	Set of laws made by a government.
Quality assurance	The maintenance of a desired level of quality in a service or product, especially by means of attention to every stage of the process of delivery or production.
Regulation(s)	A legislative act that requires a License to work in a health profession
Regulatory body/Regulator	A provincial public-sector agency formed or mandated under the terms of a legislative act related to a health profession to ensure compliance with the provisions of the act and in carrying out its purpose.
Scope of practice	Describes the procedures, actions, and processes that a healthcare practitioner is permitted to undertake in keeping within the terms of their professional license. In the case of non-regulated professions, the scope of practice is often determined by the national professional organization representing and credentialing practitioners. Sonography Canada's Scope of Practice can be found on page 16 of the Sonography Canada Professional Practice Guidelines and Member Policies .
Spatial reasoning	A category of reasoning skills that refers to the capacity to think about objects in three dimensions and to draw conclusions about those objects from limited information.
Standards of practice	Form the framework to measure the quality of care and service, practices considered essential to the provision of high-quality care, in conjunction with entry-to-practice competency statements, are used by educators to design education programs and practice assessments.

Continued on next page

Sterile technique	A set of specific practices and procedures performed to make equipment and areas free from all microorganisms and to maintain that sterility.
Technical impression	Form of communication between the sonographer and the reporting physician. The full Sonography Canada position statement can be found on page 34 of the Sonography Canada Professional Practice Guidelines and Member Policies .

Appendices



Appendix A: Examination Techniques for the Generalist Sonographer – OBSTETRICS & GYNECOLOGY

The table below applies to competency **4.2b** and lists the techniques a practitioner should use when examining the structures and characteristics noted. Within this appendix, each technique is assigned an appropriate assessment environment. These are not intended as scanning protocols.

GYN and/or OB Trimester	STRUCTURE / CHARACTERISTIC	TECHNIQUE							
		real time assessment (transvesical)	measure (2D)	M-mode	colour / power Doppler assessment	Pulsed wave (PW) Doppler assessment	measure PW Doppler	endo-vaginal	sonohysterography / hysterosonography
GYN, 1 st , 2 nd , 3 rd	Adnexa	C						C	
GYN	Bowel	A						A	
GYN, 1 st , 2 nd , 3 rd	Cervix	C						C	
GYN, 1 st	Cul-de-sacs	C						C	
GYN, 1 st	Endometrium	C	C		A	A	A	C	A
GYN, 1 st	Fallopian tubes	C						C	A
GYN	Muscles & ligaments	A						A	
GYN, 1 st , 2 nd , 3 rd	Ovaries	C	C		C	A	A	C	
GYN, 1 st , 2 nd , 3 rd	Urinary bladder	C							
GYN, 1 st , 2 nd , 3 rd	Kidneys	C							
GYN, 1 st	Uterus	C	C		A	A		C	A
GYN, 1 st	Vagina	C							
GYN	Vasculature of the female pelvis	C			A			C	
Fetal Age / Fetal Growth									
1 st	Gestational sac	C	C					C	
1 st	Fetal pole	C	C					C	
2 nd , 3 rd	Abdominal circumference	C	C						
2 nd , 3 rd	Biparietal diameter	C	C					A	
2 nd , 3 rd	Femur length	C	C						
2 nd , 3 rd	Head circumference	C	C						

Continued on next page

GYN and/or OB Trimester	STRUCTURE / CHARACTERISTIC	TECHNIQUE							
		real time assessment (transvesical)	measure (2D)	M- mode	colour / power Doppler assessment	Pulsed wave (PW) Doppler assessment	measure PW Doppler	endo- vaginal	sonohysterography / hysterosonography
Fetal Head									
2 nd , 3 rd	Anterior horn lateral ventricles	C							
2 nd , 3 rd	Atria of lateral ventricles	C	C						
2 nd , 3 rd	Cavum septi pellucidi	C							
2 nd , 3 rd	Cerebellum	C	C						
2 nd , 3 rd	Cerebral vessels	A			A	A	A		
2 nd , 3 rd	Choroid plexus	C							
2 nd , 3 rd	Cisterna magna	C	C						
2 nd , 3 rd	Falx cerebri	C							
2 nd , 3 rd	Skull	C							
2 nd , 3 rd	Thalamus	C							
2 nd , 3 rd	Third ventricle	C							
Fetal Spine									
1 st	Gross spinal development	C							
2 nd , 3 rd	Cervical spine	C							
2 nd , 3 rd	Lumbo-sacral spine	C							
2 nd , 3 rd	Thoracic spine	C							
Fetal Face									
2 nd , 3 rd	Facial profile	C							
2 nd , 3 rd	Palate	A							
2 nd , 3 rd	Mouth / lips	C							
1 st , 2 nd , 3 rd	Nasal bones	C	A						
2 nd , 3 rd	Orbits	C	C						
Fetal Neck									
1 st	Nuchal translucency	C	A						
2 nd , 3 rd	Nuchal fold	C	C						
Fetal Chest / Thorax									
2 nd , 3 rd	Diaphragm	C							
2 nd , 3 rd	Lungs	C							
2 nd , 3 rd	Thoracic shape	C							

Continued on next page

GYN and/or OB Trimester	STRUCTURE / CHARACTERISTIC	TECHNIQUE							
		real time assessment (transvesical)	measure (2D)	M-mode	colour / power Doppler assessment	Pulsed wave (PW) Doppler assessment	measure PW Doppler	endo-vaginal	sonohysterography / hysterosonography
Fetal Heart									
1 st , 2 nd , 3 rd	Fetal heart rate	C		C				C	
2 nd , 3 rd	Situs	C							
2 nd , 3 rd	Size	C							
2 nd , 3 rd	Axis	C							
2 nd , 3 rd	4 Chamber fetal heart	C							
2 nd , 3 rd	Aortic arch	C							
2 nd , 3 rd	Ductal arch	A							
2 nd , 3 rd	Outflow tracts	C							
2 nd , 3 rd	Three vessel view	C							
Fetal Abdomen									
2 nd , 3 rd	Adrenals	C							
2 nd , 3 rd	Aorta	C							
2 nd , 3 rd	Bowel	C							
2 nd , 3 rd	Gallbladder	C							
2 nd , 3 rd	Kidneys	C	C						
2 nd , 3 rd	Liver	C							
2 nd , 3 rd	Renal pelvis	C	C						
2 nd , 3 rd	Spleen	C							
1 st , 2 nd , 3 rd	Stomach	C							
Umbilical Cord									
1 st , 2 nd , 3 rd	Umbilical cord	C							
2 nd , 3 rd	Fetal insertion	C			A				
2 nd , 3 rd	Placental insertion	C			A				
2 nd , 3 rd	Vessels	C			A				
Fetal Pelvis									
1 st , 2 nd , 3 rd	Urinary bladder	C							
2 nd , 3 rd	Genitalia	C							
Fetal Skin									
2 nd , 3 rd	Contour	C							
2 nd , 3 rd	Thickness	C	A						

Continued on next page

GYN and/or OB Trimester	STRUCTURE / CHARACTERISTIC	TECHNIQUE							
		real time assessment (transvesical)	measure (2D)	M-mode	colour / power Doppler assessment	Pulsed wave (PW) Doppler assessment	measure PW Doppler	endo-vaginal	sonohysterography / hysterosonography
Fetal Musculoskeleton									
1 st	Gross limb development	C							
2 nd , 3 rd	Feet	C							
2 nd , 3 rd	Femora	C	C						
2 nd , 3 rd	Fibula	C	A						
2 nd , 3 rd	Hands	C							
2 nd , 3 rd	Humeri	C	A						
2 nd , 3 rd	Radius	C	A						
2 nd , 3 rd	Ribs	C							
2 nd , 3 rd	Tibia	C	A						
2 nd , 3 rd	Ulna	C	A						
Placenta									
1 st , 2 nd , 3 rd	Placental location / development	C						C	
2 nd , 3 rd	Grading	C							
2 nd , 3 rd	Relation to internal os	C			C			A	
2 nd , 3 rd	Thickness	C	A						
Determination of:									
2 nd , 3 rd	Amniotic Fluid -Single Pocket Evaluation	C	C						
2 nd , 3 rd	Amniotic fluid index	C	C						
1 st , 2 nd , 3 rd	Chorionicity	C						C	
2 nd , 3 rd	Cervical length	C	C					A	
2 nd , 3 rd	Fetal lie	C							
2 nd , 3 rd	Fetal presentation	C							
1 st , 2 nd , 3 rd	Number of Fetuses	C						C	
Other									
1 st	Yolk sac	C	C					C	
3 rd	Cord Doppler	C			C	C	C		
3 rd	Amniotic fluid	C	C						
3 rd	Breathing	C							
3 rd	Fetal movement	C							
3 rd	Fetal tone	C							

Appendix B: Examination Techniques for the Generalist Sonographer – ABDOMEN

The table below applies to competency **4.2b** and lists the techniques a practitioner should use when examining the structures and characteristics noted. Within this appendix, each technique is assigned an appropriate assessment environment. These are not intended as scanning protocols.

STRUCTURE / CHARACTERISTIC	TECHNIQUE				
	real time assessment	measure (2D)	colour / power Doppler assessment	pulsed wave (PW) Doppler assessment	measure PW Doppler
Abdominal aorta	C	C	A		
Abdominal wall	C				
Adrenal glands	A				
Celiac trunk	C				
Chest and thorax	A				
Common iliac arteries	C	C	A		
Common iliac veins	A		A		
Inferior vena cava	C		A		
Liver	C	C			
Pancreas	C	A			
Peritoneal, retroperitoneal cavities / spaces	C				
Spleen	C	C			
Splenic vein	C		C		
Superior mesenteric artery	C				
Biliary System					
Gallbladder	C	C			
Common hepatic duct	C	A			
Common bile duct	C	C			
Cystic duct	A				
Intrahepatic ducts	C				
Gastrointestinal Tract					
Appendix	S				
Small bowel	A				
Large bowel	A				
Stomach	A				

Continued on next page

STRUCTURE / CHARACTERISTIC	TECHNIQUE				
	real time assessment	measure (2D)	colour / power Doppler assessment	pulsed wave (PW) Doppler assessment	measure PW Doppler
Urinary Tract					
Kidneys	C	C			
Renal arteries	S		S	S	S
Renal veins	S		S	S	S
Ureters	C				
Urinary bladder	C	C			
Prostate	C	C			
Seminal vesicles	C	C			
Liver - Vasculature					
Hepatic veins	C		C	C	
Hepatic artery	C		C	C	
Portal veins	C	C	C	C	

Appendix C: Examination Techniques for the Generalist Sonographer – SUPERFICIAL STRUCTURES

The table below applies to competency **4.2b** and lists the techniques a practitioner should use when examining the structures and characteristics noted. Within this appendix, each technique is assigned an appropriate assessment environment. These are not intended as scanning protocols.

STRUCTURE / CHARACTERISTIC	TECHNIQUE			
	real time assessment	measure (2D)	Colour / power Doppler assessment	pulsed wave (PW) Doppler Assessment
Breast	A			
Inguinal region	A			
Superficial tissues	A			
Scrotum	C	C	C	C
Lymph nodes	C			
Popliteal fossa	C			
Glands				
Salivary glands	A			
Parathyroid	A			
Thyroid	C	C	C	

Appendix D: Examination Techniques for the Generalist Sonographer – PERIPHERAL VEINS

The table below applies to competency **4.2b** and lists the techniques a practitioner should use when examining the structures and characteristics noted. Within this appendix, each technique is assigned an appropriate assessment environment. These are not intended as scanning protocols.

STRUCTURE / CHARACTERISTIC	TECHNIQUE		
	real time assessment	colour / power Doppler assessment	pulsed wave (PW) Doppler assessment
Peripheral veins, upper extremity, for DVT			
Jugular vein	S	S	S
Innominate vein	S	S	S
Subclavian vein	S	S	S
Axillary vein	S	S	
Brachial vein	S	S	
Basilic vein	S	S	
Cephalic vein	S	S	
Peripheral veins, lower extremity, for DVT			
Iliac veins	C	C	S
Common femoral vein	C	C	C
Femoral vein	C	C	C
Popliteal vein	C	C	C
Sapheno-Femoral Junction	C	C	C
Sapheno-Popliteal Junction	C	C	
Deep Calf Veins	A	A	

Appendix E: Examination Techniques for the Cardiac Sonographer

The table below applies to competency **4.2b** and lists the techniques a practitioner should use when examining the structures and characteristics noted. Within this appendix, each technique is assigned an appropriate assessment environment. These are not intended as scanning protocols.

STRUCTURE / CHARACTERISTIC	TECHNIQUE											
	2-D real time assessment	measure (2D)	M-mode	measure - M-mode	colour Doppler assessment	measure colour Doppler	pulsed wave (PW) Doppler assessment	measure PW Doppler	continuous wave (CW) Doppler assessment	measure CW Doppler	tissue Doppler assessment	measure-tissue Doppler
Abdominal situs	C											
Cardiac position	C											
Chest & thorax (adjacent, extra-cardiac)	C											
Coronary vessels	A	A			A							
Hepatic veins	C				C		C	C				
Outflow tracts	C	C			C		C	C	C	C		
Pulmonary veins	C				C		C	C				
Wall layers (endo, myo, pericardium)	C	C	S	S								
Wall segments	C	C	S									
Aorta												
Arch & branches	C	C			C							
Ascending	C	C			C				C	C		
Descending	C	C			C		C	C	C	C		
Root	C	C	S	S	C							
Atria												
Left	C	C	S	S	C							
Right	C	C			C							
Left Atrial Appendage	C											
Right Atrial Appendage	A											
Pulmonary artery												
Main pulmonary artery	C	S			C		C	C	C	C		
Bifurcation	C				A		A	A	C	A		
Septa												
Atrial	C				C		C	C	C	C		
Ventricular	C	C	S	S	C		C	C	C	C		

Continued on next page

STRUCTURE / CHARACTERISTIC	TECHNIQUE											
	2-D real time assessment	measure (2D)	M-mode	measure M-mode	colour Doppler assessment	measure colour Doppler	pulsed wave (PW) Doppler assessment	measure PW Doppler	continuous wave (CW) Doppler assessment	measure CW Doppler	tissue Doppler assessment	measure-tissue Doppler
Valves												
Aortic	C		C		C	C	C	C	C	C		
Mitral	C	S	C		C	C	C	C	C	C		
Mitral (annulus)	C										C	C
Pulmonic	C				C		C	C	C	C		
Tricuspid	C				C		C	C	C	C		
Tricuspid annulus	C		C	C							C	C
Vena cava												
Inferior	C	C	C	S	C							
Superior	A				A							
Ventricles												
Left	C	C	S	S	C							
Right	C	C	S	S	C							

Appendix F: Examination Techniques for the Vascular Sonographer

The table below applies to competency **4.2b** and lists the techniques a practitioner should use when examining the structures and characteristics noted. Within this appendix, each technique is assigned an appropriate assessment environment. These are not intended as scanning protocols.

STRUCTURE / CHARACTERISTIC	TECHNIQUES					
	real time assessment	measure (2D)	colour/power Doppler assessment	pulsed wave (PW) Doppler assessment	measure – PW Doppler	Indirect Testing (PPG, arterial pressure testing)
Abdominal vascular						
Aorta	C	C	C	C	C	
Celiac trunk	C	A	S	S	S	
Hepatic artery	C	C	C	C	C	
Superior mesenteric artery	C	A	S	S	S	
Superior mesenteric vein	S		S	S	S	
Inferior mesenteric artery	S	A	S	S	S	
Inferior mesenteric vein	S		S	S	S	
Renal artery	C	A	C	C	C	
Renal veins	C		C	C	C	
Hepatic veins	C		C	C	C	
Portal veins	C	C	C	C	C	
Splenic artery	S	S	S	S	S	
Splenic vein	C		C	C	C	
Inferior vena cava	C	S	C	C	C	
Cerebrovascular						
Common carotid artery	C	A	C	C	C	
Internal carotid artery	C	A	C	C	C	
External carotid artery	C	A	C	C	C	
Vertebral artery	C	A	C	C	C	
Subclavian artery	C	A	C	C	C	
Innominate (brachiocephalic) artery	C	A	C	C	C	
Intracranial arteries	A	A	A	A	A	
Peripheral arteries, upper extremity						
Innominate (brachiocephalic) artery	C	C	C	C	C	
Subclavian artery	C	C	C	C	C	
Axillary artery	C	C	C	C	C	
Brachial artery	C	C	C	C	C	C
Forearm arteries	C	C	C	C	C	S

Continued on next page

STRUCTURE / CHARACTERISTIC	TECHNIQUES					
	real time assessment	measure (2D)	colour/power Doppler assessment	pulsed wave (PW) Doppler assessment	measure – PW Doppler	Indirect Testing (PPG, arterial pressure testing)
Peripheral arteries, lower extremity						
Iliac arteries	C	C	C	C	C	
Common femoral artery	C	C	C	C	C	S
Femoral artery	C	C	C	C	C	S
Popliteal artery	C	C	C	C	C	S
Calf arteries	C		C	C		C
Peripheral veins, upper extremity						
Jugular vein	C		C	C		
Innominate vein	C		C	C		
Subclavian vein	C		C	C		
Axillary vein	C		C	C		
Brachial vein	C	C	C	C		
Forearm veins	C	C	C	C		
Basilic vein	C	C	C	C		
Cephalic vein	C	C	C	C		
Peripheral veins, lower extremity						
Iliac veins	C		C	C		
Common femoral vein	C		C	C		
Femoral vein	C		C	C		
Popliteal vein	C		C	C		
Calf veins	C		C	C		
Saphenous veins	C	C	C	C		
Grafts and stents						
Grafts and stents	C	C	C	C	C	

Development and Validation of the National Competency Profiles

The National Competency Profiles (NCPs) were developed and revalidated by expert committees of practitioners and educators through national surveys of practicing sonographers and employers. Minor revisions have been made to each version, based on user feedback and national changes in practice.

- First published in 2003
- Version 4.0, 2008
- Version 5.0, 2013
- Version 6.0, 2019

The process for the most recent revalidation:

- Preliminary consultation on strategic issues with the Sonography Canada Board of Directors and committees.
- Identification of proposed new competencies, wording changes for clarity, and assessment environment adjustments based upon the knowledge and experience of Revalidation Steering Committee members
- Consultation with Sonography Canada National Education Advisory Committee (NEAC) and provincial regulators regarding practice trends/changes and feedback on proposed revisions of the NCPs
- Development of survey criteria by the NCP Revalidation Steering Committee
- Survey of practitioners on the frequency of use, importance of selected competencies and expectation of competence at entry-level
- Survey of employers on current and future competency requirements for entry-level sonographers
- Preparation of an updated NCP (Version 6.0) in response to information received from surveys
- Consultation with stakeholders of NCP Version 6.0
- Approval of the document by the Board of Directors of Sonography Canada

Implementation timeframe of Version 6.0 was determined by education stakeholders and Sonography Canada.

- Based on a recommendation of the NCP 6.0 Revalidation Steering Committee, NCP 6.0 was re-issued in October 2021 (as version 6.1) to revise appendix D, removing Extracranial Arteries from the Generalist competency profile.

Acknowledgements

Revalidating and revising the National Competency Profiles (NCPs) for Version 6.0 would not have been possible without the volunteer efforts of dedicated sonographers on the NCP Revalidation Steering Committee. This revalidation was facilitated by Yardstick Assessment Strategies Inc.